VOLUME XXVI NO. 21 / NOVEMBER 10, 2004

THE NEWS CENTER FOR THE CANCER CARE TEAM

With Vioxx Gone, What is the Future for Chemoprevention with COX-2 Agents?

Page 3

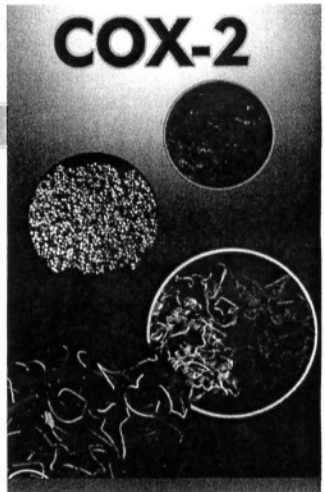

- Wilms' Tumor: Shorter Course of Chemotherapy Just as Beneficial as Current Standard of 18 Weeks 9
- Breast Conservation with Brachytherapy & Thermal Ablation Improving 42
- New Latina Resource from Living Beyond Breast Cancer 40

ADVOCACY INSIGHT: Sometimes Marketing Efforts by Advocacy Organizations Can Lose Touch with the Nuances of Appropriateness

Page 60

Multiple Myeloma: Promising Advances Target Both Tumor Cells & Bone Marrow Microenvironment

Also: Agents That Overcome Conventional Drug Resistance, New Approaches to Stem Cell Transplantation *Page 16*

The Demise of the Institute for Cancer Prevention

Closes Suddenly, Declaring Bankruptcy; Law-Enforcement Agencies Now Investigating *Page 12*

Serena Stockwell
Editor

See p. 42

(1
Ir
th
C
Pl

Oncology Times
333 Seventh Ave., 19th Fl. • New York, NY 10001
646-674-6543, fax 646-674-6500
sstockwe@LWW.com • www.oncology-times.com

Technology & Approaches to Radiotherapy

(1) Breast Cancer: Combining Radiotherapy & Tamoxifen Makes Recurrence Less Likely; (2) Lung Cancer: Radiation Before or After Chemo & Surgery Both Effective; (3) Some Children with Hodgkin's Disease Can Safely Skip Radiation; (4) Head & Neck Cancer: Hormone Therapy Fails to Cure Anemia; (5) Obese Women with Early-Stage Breast Cancer More Likely to Die than Women of Normal Weight *Page 52*

DEPARTMENTS

JOURNAL SCAN
POETRY BY CAREGIVERS
CLINICAL NOTES
PROTOCOL ALERT
SHOP TALK
CDC CANCER NEWS
CONFERENCES
CLASSIFIED

Breast Conservation

continued from page 42

and that women allow alternative treatment that is effective without disfigurement, said Steven A. Harms, MD, Professor of Radiology and Director of Imaging Research at the University of Arkansas for Medical Sciences.

"About half of breast cancers detected could potentially be treated with this method because they're small."

Two important emerging technologies, high-quality breast MRI and minimally invasive thermal ablation therapy, which includes laser, radiofrequency, and thermal techniques, could prove a powerful combination in detection and treatment of breast cancer without disfigurement, he said.

Each modality, whether radiofrequency, laser or cryotherapy, appears to stack up well with the others, noted John P. McGahan, MD, Professor of Diagnostic Radiology and of Surgery at the University of California, Davis.

With current technology radiofrequency tends to create a larger lesion and coagulates a bigger tumor than laser.

With a 17-gauge radiofrequency needle, practitioners can treat an area of 25 cm. In contrast, lasers tend to create a smaller area of necrosis and may require multiple treatments. They may also have a larger learning curve compared with radiofrequency, Dr. McGahan said.

Regardless of the therapy, it remains to be seen how best to follow up these thermal ablation treatments, whether MRI with contrast or mammography.

Effective, Outpatient, Minimal Discomfort, Good Cosmetic Result

Dr. Harms believes women will begin to demand thermal ablation because it's an effective outpatient procedure with minimal discomfort that delivers a good cosmetic result.

He and his colleagues have performed more than 50 laser thermal ablations on patients with breast cancer followed by traditional surgery. Serial section magnetic resonance images and pathological studies of the breasts indicated that the procedure successfully destroyed all of the cancerous cells.

A high-contrast, high-resolution MRI such as ROtating Delivery of Excitation Off-resonance (RODEO) is essential for defining the extent of the cancer and its margins and excluding it from the rest of the breast, Dr. Harms emphasized.

With a 17-gauge radiofrequency needle, practitioners can treat an area of 2.5 cm. In contrast, lasers tend to create a smaller area of necrosis and may require multiple treatments. They may also have a larger learning curve compared with radiofrequency.

A few days after treatment, the patient can look at herself in the mirror and see that her breast looks as it did before therapy. Patients recover quickly, and most resume normal activities the next day.

As a result, his institution plans to offer thermal ablation as a treatment for solitary small tumors 1.5 cm or smaller. Following the procedure, patients typically receive radiation therapy and/or chemotherapy, just as they would following surgical treatment of breast cancer.

Dr. McGahan and his colleagues are evaluating radiofrequency treatment of lesions up to 1.5 cm and are achieving 100% necrosis. Physicians are following up treatment with resection to determine the effectiveness of the therapy.

RSNA Media Briefing

Breast Conservation with Brachytherapy & Thermal Ablation Improving

By Heather Lindsey

NEW YORK CITY—Brachytherapy and thermal ablation techniques may offer women with small breast tumors an effective treatment option that avoids disfigurement or unnecessary mastectomies, according to speakers here at a Radiological Society of North America (RSNA) media briefing.

Many women are unnecessarily undergoing mastectomy because they want to avoid the six to seven weeks of conventional external-beam radiation therapy associated with breast-conserving therapy, noted Robert R. Kuske, MD, a radiation oncologist with Arizona Oncology Services.

Robert R. Kuske, MD, has been conducting clinical trials of brachytherapy for the last 13 years and has found ways to make the treatment more accessible in the oncology clinic. For example, image-guided therapy and using a single catheter balloon or MammoSite have helped to ensure that radiation oncologists across the country can use the technique, he said.

However, lumpectomy followed by brachytherapy offers women the option of preserving their breast while undergoing less than a week of localized radiation treatment.

"Since [brachytherapy] radiation is inside the breast, it can deliver six and a half weeks worth of radiation treatment in just four or five days," he explained.

In an interview, another radiation oncologist, Martin Keisch, MD, of Mount Sinai Medical Center in Miami Beach, said that the difference is one week of treatment to roughly a quarter of the breast as opposed to six and a half weeks of treatment to the whole breast.

Despite 20 years of studies demonstrating no difference in survival rates between women receiving mastectomy or lumpectomy followed by radiation therapy, only 55% of women opt for the latter treatment even though about 80% are eligible for breast-conserving therapy, Dr. Kuske said.

In addition to the inconvenience of weeks of radiation therapy, women fear the side effects of whole-breast irradiation to uninvolved breast tissue, skin, lungs and the heart, he noted.

Brachytherapy allows for a highly effective dose of radiation delivered to the lumpectomy cavity and reduces exposure to surrounding tissues that don't need it. Additionally, the treatment neither interferes with daily activities such as work nor requires repeated visits to the clinic as is the case with external-beam radiation.

More Convenient for Those in Rural Areas & Those for Whom 7 Weeks of RT Is Difficult to Arrange

Brachytherapy and breast-conservation therapy may be especially convenient for women living in rural areas and for those whose lifestyles or occupations will not accommodate up to seven weeks of radiation treatment, Dr. Kuske remarked.

Brachytherapy may also be the treatment of choice for women with silicone breast implants, who tend to encounter difficulty during the six to seven weeks of external-beam radiation due to scar tissue, he said. The treatment is also easy to perform in women with large breasts.

Women are eligible for breast brachytherapy if their tumor size is 3 cm or smaller, as long as the cells do not reach the surgical margin. Up to three lymph nodes under the arm may be involved.

Women are eligible for breast brachytherapy if their tumor size is 3 cm or smaller, as long as the cells do not reach the surgical margin. Up to three lymph nodes under the arm may be involved.

However, if patients are needle phobic, they won't do well with this therapy, Dr. Kuske said. It is an invasive technique, but still, the goal is for it to be painless and bloodless.

"Most of the time, we achieve that," he said, adding that pock marks remain for up six months and usually completely go away.

Dr. Kuske and his colleagues have been conducting clinical trials of brachytherapy for the last 13 years and have found ways to make the treatment more accessible in the oncology clinic.

For example, image-guided therapy and using a single catheter balloon or MammoSite have helped to ensure that radiation oncologists across the country can use the technique.

"Brachytherapy is being done increasingly around the country," Dr. Keisch said, noting that practitioners at his institution in Miami Beach most often use the MammoSite device, which received FDA approval in 2002.

Multicatheter-based implants have, to date, generated outstanding clinical results, but the practice has not become widespread because the treatment is technically challenging, he explained.

Generally, radiation oncologists are too busy to learn the multicatheter implantation or do not want to go into the operating room for an invasive technique, he said. "This has slowed down the whole process of acceptance."

MammoSite

MammoSite is a much simpler method of partial breast irradiation, Dr. Keisch said. The recurrence rate to date is no worse than with whole breast irradiation, according to data at five years follow-up.

Dr. Kuske has led three trials investigating brachytherapy, which have shown low toxicity and cancer recurrence rates of only 3% to 4%.

For example, a Phase II study presented at this year's ASCO Annual Meeting found a less than 1% per year local failure rate in 99 patients treated with brachytherapy after a median follow up of 3.7 years.

The actuarial four-year breast and nodal recurrence rate was 3%. Distant metastasis occurred in six patients, for an actuarial four-year rate of 6%. Disease-free survival and overall survival were 85% and 93%, respectively, at four years.

Contralateral breast cancer developed in three patients, while six patients had non-breast second primaries.



Steven A. Harms, MD, said that two important emerging technologies, high-quality breast MRI and minimally invasive thermal ablation therapy, which includes laser, radiofrequency, and thermal techniques, could prove a powerful combination in detection and treatment of breast cancer without disfigurement.

The recurrence rates for standard external-beam radiation are also about 1% per year, Dr. Kuske noted.

Dr. Kuske is currently serving as a co-principal investigator of an upcoming Phase III clinical trial by the National Surgical Adjuvant Breast and Bowel Project and the Radiation Therapy Oncology Group comparing accelerated partial breast irradiation and external-beam radiation.

An increasing number of centers are learning this technology, he said, noting that he hopes the Phase III trial will help ensure that more clinics start to use the treatment.

Thermal Ablation

In addition to the benefits of brachytherapy for breast conservation, researchers are also studying image-guided thermal techniques, such as radiofrequency ablation, laser ablation, and cryotherapy, which destroy tumors without open surgery or scarring.

Physicians hope that all cancer will be detected when small and curable

(continued on page 44)

HIFU

High-intensity focused ultrasound (HIFU) is another noninvasive treatment that may prove to be promising, Dr. McGahan noted. This therapy induces complete coagulative necrosis of a tumor at a depth through the intact skin.

In a study last year in *British Journal of Cancer (2003;89:2227-2233)* researchers in China randomized 48 women with biopsy-proven breast cancer to HIFU followed by modified radical mastectomy and to a control group of modified radical mastectomy alone.

No severe side effects occurred in the HIFU-treated patients. "There was one skin burn out of 23 patients," Dr. McGahan noted. Pathologic findings revealed that HIFU-treated tumor cells underwent complete coagulative necrosis, and tumor vascular vessels were severely damaged.

"Patients in this trial did very well," he said.

He added, though, that regardless of the therapy, it remains to be seen how best to follow up these thermal ablation treatments, whether MRI with contrast or mammography.

To Reach *Oncology Times*:

■ For Editorial, Permissions, or Publishing Matters:
Oncology Times, 333 Seventh Ave., 19th Floor, New York, NY 10001
646-674-6544, fax 646-674-6500
e-mail: OT@LWW.com

■ For Subscription Information and Changes of Address:
Lippincott Williams & Wilkins
16522 Hunters Green Parkway
Hagerstown, MD 21740, 800-638-3030

■ For Classified Advertising:
Melissa Moody, LWW, 351 West Camden, Baltimore, MD 21201, 800-269-4339, fax 410-528-4452, e-mail: mmoody@LWW.com

■ For Information about Reprints:
Jim Rosenbaum, Wolters Kluwer Health, 770 Township Line Rd., Suite 300, Yardley, PA 19067, 267-757-3554, fax 267-757-3490
jrosenbaum@pharma.wkhealth.com